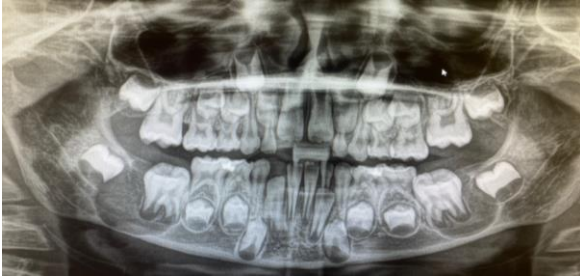

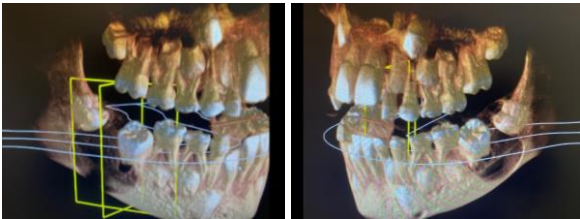
Bilateral Mandibular Buccal Bifurcation Cysts

Pooyan Sadr-Eshkevari: DDS, MD; University of Louisville, USA



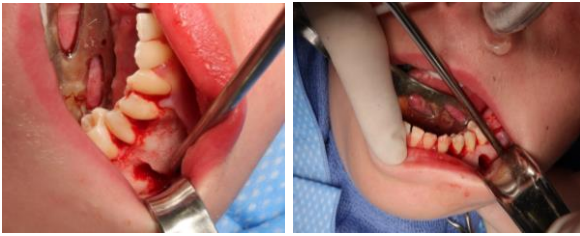Presentation

9 year old Caucasian male with painful bilateral mandibular swellings



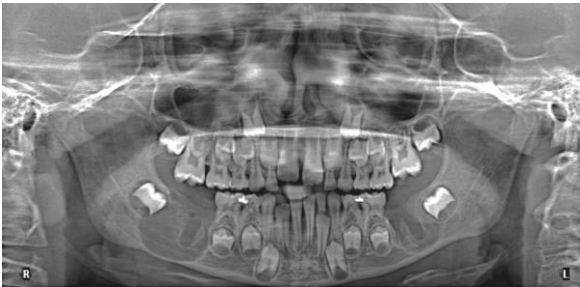Work-up

Panoramic
occlusal
CBCT



Intervention

Complete enucleation and curettage was not possible without extraction of #19 and #30



Follow-up

1 month
Resolution of symptoms

- age and site specific, buccal of molar bifurcation in ~9 yr old
- clinical and radiographic exams may be enough for diagnosis
- treatment:
 - a. doing nothing
 - b. probing (micromarsupialization) and regular irrigation
 - c. enucleation without extraction
 - d. enucleation with extraction
- expected to resolve in ~12 months