

Title: Innovative Use of Dermal Substitute to Improve Post-op Pain Control in a Patient Undergoing Excision of Tongue T1 Squamous Cell Carcinoma.

Authors: Sam R. Caruso DMD¹; Anastasiya Quimby MD, DDS²
1 First year resident

2 Assistant Professor, Director of Microvascular Surgery Program

Authors have no conflict of interest to disclose

Department of Oral & Maxillofacial Surgery, Nova Southeastern University/Broward General Medical Center, Fort Lauderdale, FL, USA

Introduction:

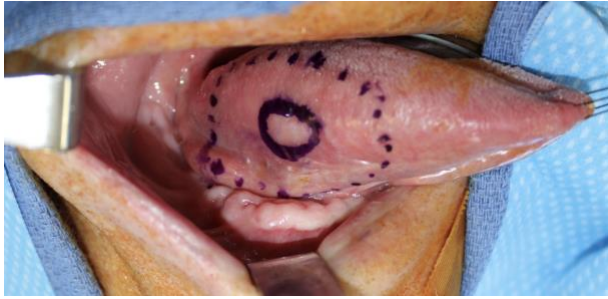Defects resulting from excision of minor premalignant or malignant tongue lesions are often left to heal by secondary intention or on occasion a skin graft is utilized. The most common patient complaint in the immediate postoperative period is significant pain that interferes with oral intake and is challenging to control with oral and topical pain agents. Dermal scaffolds have been in use in cutaneous and oral wounds to improve healing and reduce scarring. Due to the mechanical barrier that a dermal scaffold provides and its property of supporting cellular and vascular ingrowth it was speculated that coverage of large superficial tongue defects may improve post-operative pain during oral intake in the immediate postoperative period as well as facilitate quicker healing.

Objective:

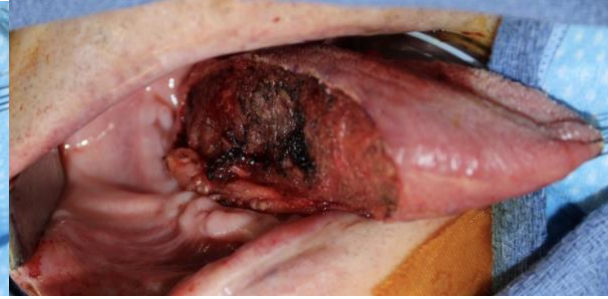Assess postoperative pain level, healing time and scarring in a patient who underwent resection of T1 squamous cell carcinoma and coverage with dermal scaffold.

Result:

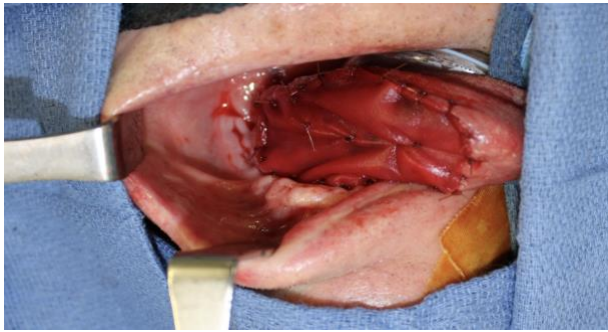
70 y.o. male patient with T1 squamous cell carcinoma of right tongue underwent wide local excision and application of dermal scaffold that was secured with chromic gut sutures in interrupted fashion with tacking stitches. At his first week follow-up he reported not taking any pain medication after the second postoperative day. At the second follow up, the scaffold was noted to be partially incorporated. Patient reported pain 4-6/10 when eating that was adequately controlled with over-the-counter pain medication. At the third week follow up patient declined needing to take pain medicine and site appeared to be healing well.



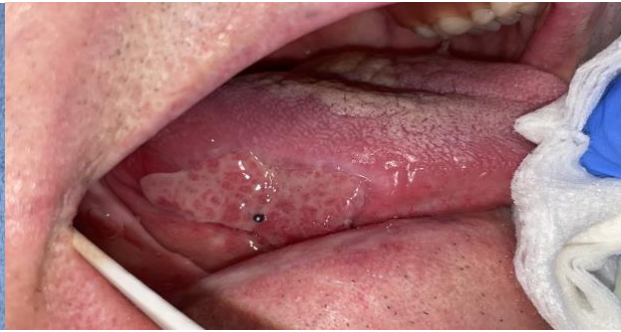Pic 1: PreOp markings



Pic 2: S/p excision



Pic 3: s/p dermal scaffold application



Pic 4: 3 weeks post-op

Conclusion:

This is a first report of using dermal scaffold as means of improving postoperative pain management in patients undergoing superficial tongue lesion excisions. Although a single patient report is inadequate for making any recommendations, this experience is encouraging and further studies in this area would be of interest.

Citations:

1. Farrier JN, Beech AN. Use of a bolster to secure a skin regeneration system on the tongue. *Br J Oral Maxillofac Surg*. 2017 May;55(4):433-434. Epub 2016 Oct 22.

2. Gravvanis A, Kakagia D, Katsikeris N, Tsoutsos D. Dermal Matrix for Intraoral Lining Following Composite Mandibular Defect Reconstruction With Chimeric Fibular Osseocutaneous Flap. J Craniofac Surg. 2016 Oct;27(7):1711-1714.
3. Pontini A, Reho F, Giatsidis G, Bacci C, Azzena B, Tiengo C. Multidisciplinary care in severe pediatric electrical oral burn. Burns. 2015 May;41(3):e41-6.. Epub 2015 Feb 21.
4. Rúa González L, de Villalaín Álvarez L, Novoa Gómez A, de Vicente Rodríguez JC, Peña González I. Use of Integra in oral reconstruction: a case series. Oral Surg Oral Med Oral Pathol Oral Radiol. 2018 Mar;125(3):e72-e75. Epub 2017 Nov 15.

Integra for Tongue Reconstruction

1. <https://pubmed.ncbi.nlm.nih.gov/29248423/>
2. <https://pubmed.ncbi.nlm.nih.gov/27763972/>
3. <https://pubmed.ncbi.nlm.nih.gov/27780612/>
4. <https://pubmed.ncbi.nlm.nih.gov/25716757/>
- 5.

Meeting Sparknotes: 12/2/20

3 patients who can be included

Look up diagnosis - demographic info

Demonstrate the results of using integra for partial glossectomy of wide local excision of tongue recovery.

Reason - tongue is notoriously painful

Leaving exposed muscle, you can leave it granulate in by itself.

Downside is that it takes a long time and it hurts.

Issues with resuming diet, pain meds, resume talking delayed.

Collagen matrix starts as scaffold. Induces imbibition - thought process if we put on tongue it starts as mechanical barrier in early postop period. Then #2 you have encouraged epithelial cell migration which results. In quicker healing.

Reduce pain meds, reduce time discomfort, facilitate quicker recovery.

Do the skeleton. Put things in your words.