

# CONSERVATIVE MANAGEMENT OF ADVANCED MANDIBULAR OSTEORADIONECROSIS WITH MILD CLINICAL PRESENTATION AFTER 17 YEARS OF ONCOLOGICAL TREATMENT

W.E. Bernaola-Paredes<sup>1</sup>; H.R.M. Veronese<sup>2</sup>; V.B.Filho<sup>1</sup>; I.S. Martins<sup>3</sup>; A.C.A. Pellizzon<sup>1</sup>.

<sup>1</sup>Department of Radiation Oncology, A.C. Camargo Cancer Center, Brazil.

<sup>2</sup>Department of Stomatology, School of Dentistry, UNIFAMINAS, Brazil.

<sup>3</sup>Department of Oral and Maxillofacial Surgery, Hospital Sirio Libanes, Brazil.

No conflict of interest

## INTRODUCTION

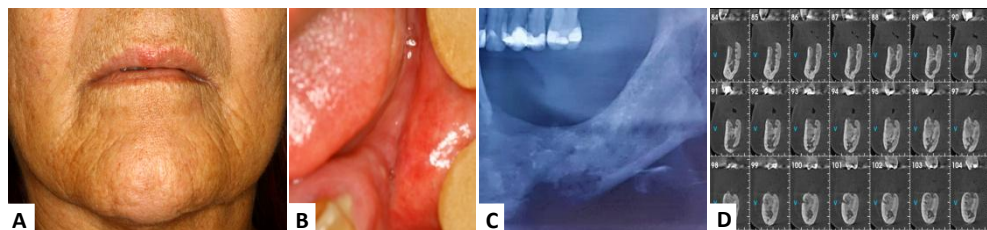
Osteoradionecrosis (ORN) of the jaws is a late complication of radiotherapy of the head and neck, with major prevalence in the mandible <sup>1</sup>. The treatment of the condition is controversial, ranging from non-surgical management to extensive surgical resections with reconstruction <sup>2</sup>. Drug therapy with PENTO protocol has shown satisfactory clinical results, including advanced ORN lesions, associated with adjuvant therapies <sup>3</sup>.

## OBJECTIVE

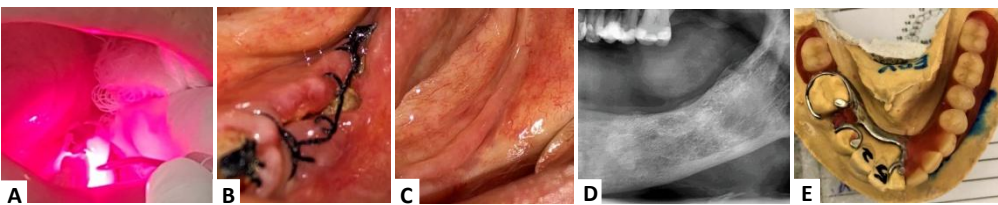
The present case report aims to describe the conservative management performed in an advanced mandibular ORN lesion with mild clinical presentation that consists in the use of PENTO protocol associated to other adjuvant therapies.

## CASE REPORT

A 62 years-old afro-descendent female patient with a history of squamous cell carcinoma of the left floor of the mouth, who was submitted to resective surgery, ipsilateral radiotherapy and concomitant chemotherapy 17 years ago who complained about toothache and the necessary of oral rehabilitation with dental implants in the left residual alveolar ridge.



**Figure 1:** Clinical and imaging features of initial lesion. **A** Extraoral examination with mild facial edema on left side. **B** Intraoral examination with intact alveolar mucosa and slight purulent drainage associated with tooth 33. **C** Orthopantomography (OP) showed an extensive destruction of left mandible bone and mixed areas of sequestration. **D** Sagittal slices by CT showed pathological fracture of mandibular baseline.



**Figure 2:** Conservative management and follow-up. **A** Antimicrobial Photodynamic Therapy (aPDT) performed at perioperative of sequestrectomy for local decontamination. **B** Primary mucosal wound closure. **C** Two month's follow-up showed normal mucosa clinical aspect. **D** Bone regeneration could be observed at OP imaging after seven month's follow-up. **E** Removable partial denture (RPR) prosthesis was placed exclusively for improving aesthetic appearance initially.

## CONCLUSION

PENTO protocol could be considered as a feasible choice for treatment of advanced ORN. Adjuvant therapies have been used in order to improve healing process and local condition after surgical debridement. However, cohort prospective studies such as randomized clinical trials (RCT) with greater sample are necessary for clarifying the role of PENTO protocol itself associated or not with these therapies

## BIBLIOGRAPHY

(1) Wang TH, Liu CJ, Chao TF, Chen TJ, Hu YW. Risk factors for and the role of dental extractions in osteoradionecrosis of the jaws: A national-based cohort study. *Head Neck*. 2017;39(7):1313–21. (2) Raggio BS, Winters R. Modern management of osteoradionecrosis. *Curr Opin Otolaryngol Head Neck Surg*. 2018 Aug;26(4):254–9. (3) Zhang Z, Xiao W, Jia J, Chen Y, Zong C, Zhao L, et al. The effect of combined application of pentoxifylline and vitamin E for the treatment of osteoradionecrosis of the jaws: a meta-analysis. *Oral Surg Oral Med Oral Pathol Oral Radiol*. 2020;129(3):207–14.